

MULTIFOCAL FIBROSCLEROSIS WITH LUNG, MEDIASTINAL, PANCREATIC AND RETROPERITONEAL INVOLVEMENT IN A 58-YEAR-OLD MAN

M. Romagnoli, V. Poletti

Interventional Pulmonology, Department of Thoracic Diseases, Forlì, Italy

A 58-year-old man, architect, mild current smoker (7 p/y), was referred to the Interventional Pulmonology Clinic for a lung opacity of the right lower lobe found on a chest radiograph. He had experienced gradually progressive exertional dyspnoea for >3 months. He denied fevers, cough, weight loss, chest pain, or haemoptysis.

His history was significant for recurrent episodes of post-prandial abdominal pain in 2002 and 2003, when an endoscopic retrograde cholangiopancreatography revealed a multifocal stenosis of the main pancreatic duct, treated by a stent positioning, with complete recovery of the abdominal symptoms.

At the admission in the clinic, a physical examination revealed a heart rate of 70 beats/min, a blood pressure of 145/80 mmHg, and a room air oxygen saturation of 98%. There was no cervical nor axillary lymphadenopathy. Chest auscultation revealed lower right inspiratory crackles. The findings of a cardiac and abdominal examination were unremarkable. Laboratory findings showed an increase of erythrocyte sedimentation rate (40 mm/h), C-reactive protein level (2.03 mg/dl), γ -proteins (20.5%), thy-

roglobulin antibodies (19 UI/ml) and circulating immune complexes (20.40 mcg/dl). Blood gas analysis and pulmonary function test were normal.

The CT scan of the chest showed the presence of a mass in the posterior segment of the right lower lobe, with airy bronchogram (Fig. 1), and enlarged mediastinal lymph nodes. The abdominal CT scan revealed the presence of a retroperitoneal, left perirenal mass turning round iliac vessels, with a major axis of 4 cm. Combined PET-CT scan revealed the presence of areas of increased (18)F-FDG uptake in the mediastinal, right pulmonary hilar lymph nodes

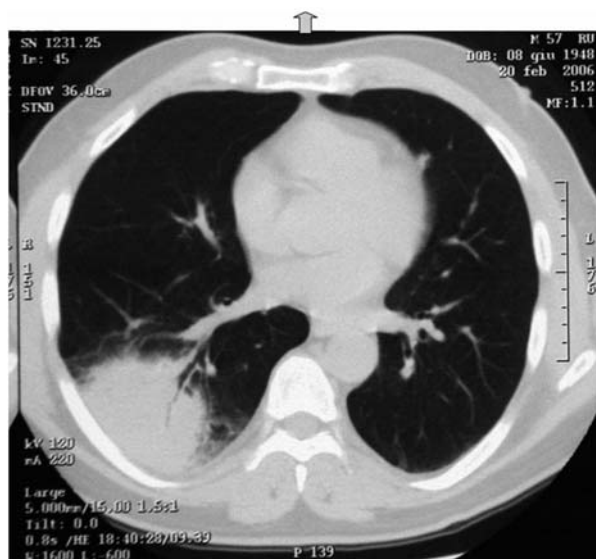


Fig. 1. Chest CT scan showing a lung mass in the posterior segment of the right lower lobe, with airy bronchogram.

Received: 17 November 2008

Accepted after Revision: 7 June 2009

Correspondence: Dr. Venerino Poletti

Interventional Pulmonology, Department of Thoracic Diseases,

GB Pierantoni - L. Morgagni Hospital, Forlì, Italy

Tel. +39 0543 735042

Fax +39 0543 735039

E-mail: v.poletti@ausl.fo.it

(mean SUV 2.83 and 3, respectively), lower right pulmonary lobe (mean SUV 3.35) (Fig. 2), and around the left iliac vessels (mean SUV 7.75).

Patient underwent bronchoscopy with transbronchial lung biopsies of the right lung mass. Histology showed the presence of young, myxoid granulation tissue in the alveolar spaces, with embedded spindle cells. The myxoid stroma and cellular fibrous tissue appeared infiltrated by lymphocytes,

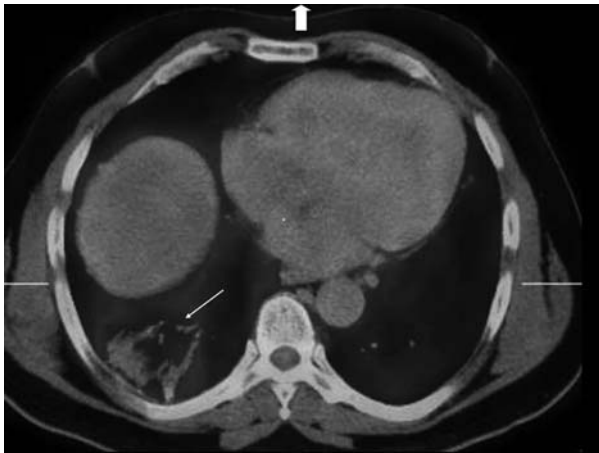


Fig. 2. Combined PET-CT scan showing the presence of areas of increased (18)F-FDG uptake in the the lower right pulmonary lobe (mean SUV 3.35) (arrow), and in mediastinal and right pulmonary hilar lymph nodes (mean SUV 2.83 and 3, respectively).

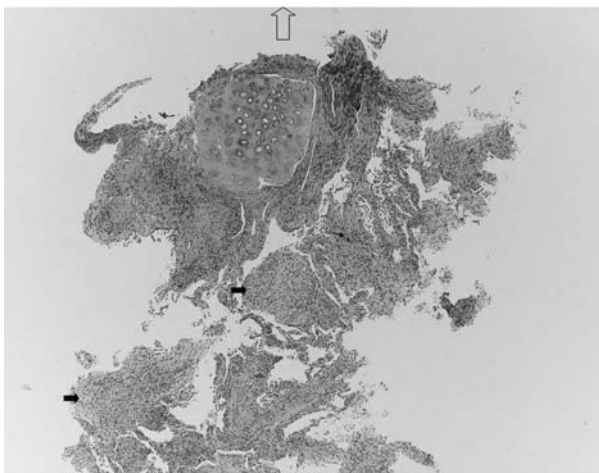


Fig. 3. Transbronchial histological findings of the right lung mass showing young granulation tissue in the alveolar spaces (thick arrows), interstitial inflammation consisting mainly of lymphocytes, and scattered Touton-like multinucleated giant cells (thin arrows) (Hematoxylin-Eosin, magnification X 4).

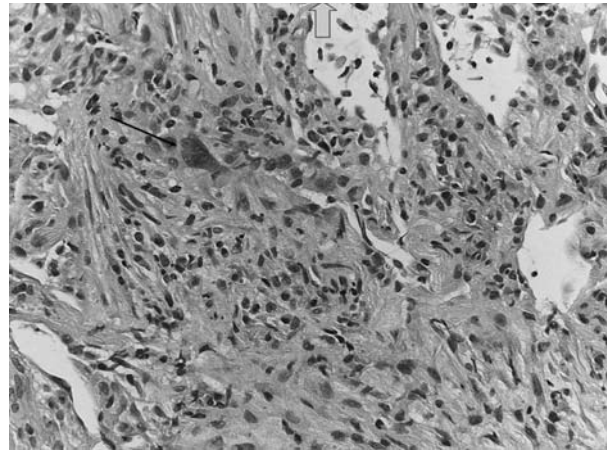


Fig. 4. Transbronchial histological findings with scattered Touton-like multinucleated giant cells (arrow), at higher power (Hematoxylin-Eosin, magnification X 20).

plasma cells, foamy macrophages, and scattered Touton-like multinucleated giant cells (Figs. 3 and 4). At immunocytochemistry, spindle cells resulted positive for vimentin and actin (myofibroblast phenotype).

What is the diagnosis?

Histological diagnosis was *Inflammatory pseudotumor – Organizing pneumonia subtype*.

The final clinical diagnosis was *Multifocal fibrosclerosis* with lung, mediastinal, and retroperitoneal involvement.

DISCUSSION

Multifocal fibrosclerosis, also known as “Immunoglobulin G4-related disease”, is a rare syndrome of unknown cause, characterized by a fibroproliferative disorder involving multiple organ systems. More common presentations include mediastinal fibrosis, retroperitoneal fibrosis, orbital pseudotumor, Riedel thyroiditis, and sclerosing cholangitis, but almost every organ can be involved. Lung involvement is not a common presentation of multifocal fibrosclerosis, only few case reports have been previously described.

Clinical and radiologic manifestations depend on the site of the fibroproliferative involvement, sometimes presenting as infiltrative mass lesions mimicking malignancies.

In this case, the patient was referring dyspnoea and showed at the CT scan of the chest a pulmonary mass with airy bronchogram, and enlarged mediastinal lymph nodes, mimicking an infectious pneumonia, or a unilateral cryptogenic organizing pneumonia (COP), or a lung malignancy. The histology at transbronchial biopsies excluded malignancies or a pattern consistent with pneumonia, and could be consistent with COP. The findings of Touton-like multinucleated giant cells and spindle cells positive for vimentin and actin were strongly suggesting for an Inflammatory pseudotumor. Since imaging was revealing a multifocal involvement (pulmonary and retroperitoneal), we definitely excluded COP and we assumed that the retroperitoneal lesion was consistent with the lung disease, and with the more common and frequent presentation of the retroperitoneal fibrosis. Thus, it was hypothesized that the multifocal stenosis of the main pancreatic duct experienced previously by the patient was already a manifestation of the multifocal fibrosclerosis.

Treatment options are not definitely indicated, due to the rarity of the disease. Medical options may include corticosteroid and other immunosuppressive treatments, e.g. azathioprine, cyclophosphamide, cyclosporine. Sometimes, surgical treatment is needed in the presence of obstructive and compressive effects of the fibrous masses.

The clinical course of multifocal fibrosclerosis is not well defined, and is quite variable. In this patient, treatment with tapering prednisone (0.75 mg/kg/die) resulted after six months in a CT scan significant reduction of the pulmonary and retro-

peritoneal masses, showing a slow and not complete response to corticosteroid treatment, as frequently observed in the multifocal fibrosclerosis.

REFERENCES

1. Hamed G, Tsushima K, Yasuo M, et al. Inflammatory lesions of the lung, submandibular gland, bile duct and prostate in a patient with IgG4-associated multifocal systemic fibrosclerosis. *Respirology* 2007; 12 (3): 455-7.
2. Leung WS, Yuen NW, Chan VL, Chu CM. A 55-year-old man with fever together with submandibular and lung masses. *Chest* 2006; 129 (2): 488-92.
3. Fukuda W, Kimura M, Akaogi T, et al. Multifocal fibrosclerosis: retroperitoneal fibrosis associated with a suprasellar tumor and pachymeningitis. *Intern Med* 2003; 42 (10): 1006-10.
4. Oguz KK, Kiratli H, Oguz O, Cila A, Oto A, Gokoz A. Multifocal fibrosclerosis: a new case report and review of the literature. *Eur Radiol* 2002; 12 (5): 1134-8.
5. Singh RS, Dhaliwal RS, Puri D, Behera D, Das A. Inflammatory pseudotumour of the lung: report of a case and review of literature. *Indian J Chest Dis Allied Sci* 2001; 43 (4): 231-4.
6. Szarf G, Bluemke DA. Case 83: multifocal fibrosclerosis with mediastinal-retroperitoneal involvement. *Radiology* 2005; 235 (3): 829-32.
7. Taniguchi T, Kobayashi H, Fukui S, Ogura K, Saiga T, Okamoto M. A case of multifocal fibrosclerosis involving posterior mediastinal fibrosis, retroperitoneal fibrosis, and a left seminal vesicle with elevated serum IgG4. *Hum Pathol* 2006; 37 (9): 1237-9; author reply 1239.
8. Tsuboi H, Inokuma S, Setoguchi K, et al. Inflammatory pseudotumors in multiple organs associated with elevated serum IgG4 level: recovery by only a small replacement dose of steroid. *Intern Med* 2008; 47 (12): 1139-42.
9. Yamashita K, Haga H, Kobashi Y, Miyagawa-Hayashino A, Yoshizawa A, Manabe T. Lung involvement in IgG4-related lymphoplasma-cytic vasculitis and interstitial fibrosis: report of 3 cases and review of the literature. *Am J Surg Pathol* 2008; 32 (11): 1620-6.
10. Inoue D, Zen Y, Abo H, et al. Immunoglobulin G4-related lung disease: CT findings with pathologic correlations. *Radiology* 2009; 251 (1): 260-70. Epub 2009 Feb 12.